

# Dilated Cardiomyopathy Associated with Toluene Abuse

Mutlu Vural<sup>a</sup> Kultegin Ogel<sup>b</sup>

<sup>a</sup>Kirsehir State Hospital Cardiology Clinic, Kirsehir, and <sup>b</sup>Bakirkoy Neurologic and Psychiatric Disease Hospital, Volatile Agent Abuse Therapy Clinic, Istanbul, Turkey

© Free Author Copy - for personal use only

ANY DISTRIBUTION OF THIS ARTICLE WITHOUT WRITTEN CONSENT FROM S. KARGER AG, BASEL IS A VIOLATION OF THE COPYRIGHT.

Written permission to distribute the PDF will be granted against payment of a permission fee, which is based on the number of accesses required. Please contact [permission@karger.ch](mailto:permission@karger.ch)

## Key Words

Dilated cardiomyopathy · Toluene

## Abstract

The use of paint thinner and glue to achieve an euphoric state has been associated with serious social and health problems in children and young adults. We present the case of a 21-year-old man with dilated cardiomyopathy occurring following abuse of paint thinner and glue containing toluene as main compound. After cessation of toluene abuse, the patient recovered rapidly and completely. Because of the increasing prevalence of toluene abuse, harmful effects of this volatile agent on the heart are also discussed.

Copyright © 2006 S. Karger AG, Basel

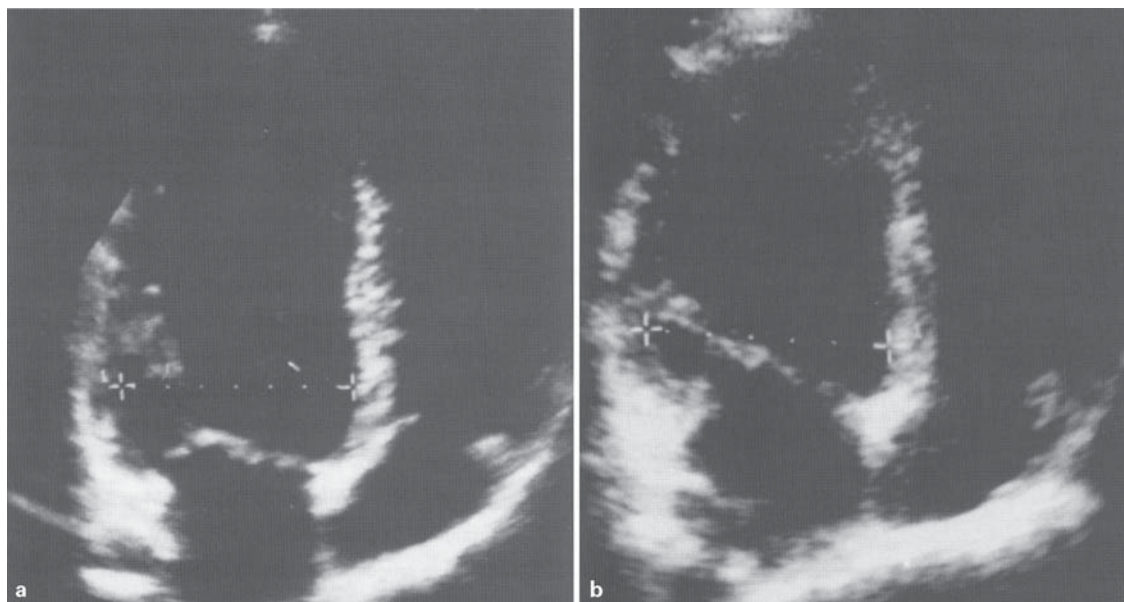
## Introduction

Since the 1960s, volatile inhalants have become increasingly popular as drugs of abuse among children and young adults, particularly sniffing of adhesives. Since volatile inhalants are included in common household products and are relatively inexpensive, paint thinner and adhesives are now among the most widely used stimulants in Turkey and many developing countries. In a recent study, the prevalence of volatile substance abuse was 73% among homeless children and 5% among second-grade

students in high schools in İstanbul, the largest metropolitan area of Turkey [1, 2]. The number of volatile substance addicts in Turkey has been estimated at 50,000 [3]. However, recent data have indicated an increase in this number. In the Western World, e.g. Britain, 3–5% of the 15-year-old children have at least experimented with volatile inhalants at any period of their life. Moreover, in this age group, 1 of 250 children has been treated at different kinds of specialized hospitals across the country due to addiction to adhesive substance sniffing [4]. Apart from the developing countries where volatile substance abuse has already reached a high prevalence, there is also an increased tendency towards volatile substance abuse in developed countries.

Being highly lipophilic, it can easily enter and affect the lipid-rich nervous system after being inhaled. Permanent damage to the central nervous system, heart, liver, kidney and lungs may ensue following toluene exposure [5–12]. Cardiotoxicity, e.g. arrhythmia, sudden death, myocardial infarction [13–15], cardiomyopathy [16] and fatal acute myocarditis [17], has often been ignored.

There is a paucity of data on toluene-induced cardiomyopathy. We report the case of a 21-year-old toluene addictive with dilated cardiomyopathy. Symptomatic and echocardiographic improvements were observed and documented after stopping toluene abuse. Toluene inhalation was responsible for the etiopathogenesis of cardiomyopathy in our patient who has been clinically stable in the absence of toluene use during the following 3 years.



**Fig. 1.** **a** During volatile substance abuse, left-ventricular diameter was increased (6.2 cm) in the apical four-chamber view. **b** After 6 months of toluene abstinence, the same projection demonstrated that the left-ventricular diastolic diameter was within normal limits (5.5 cm).

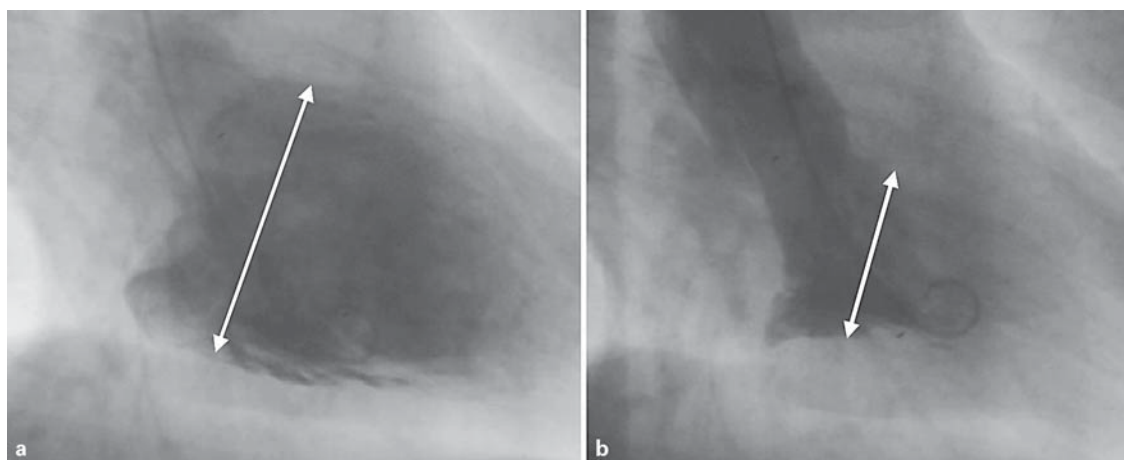
## Case Report

After running away from home at the age of 10, our 21-year-old male patient lived mainly in the streets of Istanbul. During these 11 years, the patient inhaled volatile substances for more than 10 years: 1 liter of paint thinner per day in cold seasons and two tubes of 50-ml glue per day in warm seasons, but he stopped his volatile substance abuse for 2–3 months while visiting his family. During this time, he felt better and gained weight. Moreover, his appetite increased and his pallor also vanished.

At the time of the first examination, he had given up living in the street and started to live under the auspices of a non-profit organization. He presented at the infirmary of this organization with complaints of shortness of breath while climbing uphill or playing football, quickly getting tired in other activities, and swelling and pain in the abdomen. At the infirmary, irregular pulse was noted and he was referred to our hospital for further examination. He reported to have had these complaints for 3–4 years. However, his symptoms became worse during the last 2 months. Apart from him, no family history of serious health problems was reported in his parents and seven siblings. On physical examination, his blood pressure was 110/60 mm Hg and his pulse rate was irregular at 55 beats/min. The liver exceeded the costal margin by 2 cm and was painful in deep palpation. Other findings were normal. No abnormality was observed in blood counts, erythrocyte sedimentation rate, urinalysis or biochemical blood analysis. Bigeminal ventricular extrasystoles and incomplete right bundle branch block were observed in electrocardiography. Echocardiographic examination showed that diastolic and systolic diameters of the left ventricle were 6.2 and 4.6 cm, respectively; the posterior wall and interventricular septum were 0.75 cm thick, the mitral valve was mildly

regurgitating, the left ventricle was globally hypokinetic and its ejection fraction was 40% (fig. 1a). In the light of these findings, dilated cardiomyopathy was diagnosed. Treatment started with the vaccination of the patient with influenza and pneumococcus vaccines and the administration of enalapril 5 mg b.i.d. and aspirin 80 mg once daily. The dose of enalapril was increased to 10 mg b.i.d. at the follow-up examination done 10 days later. His compulsory military duty was postponed due to the presence of cardiomyopathy. The institution where the patient lived confirmed that he did not use any volatile substances during treatment. Echocardiography after 6 months of treatment demonstrated a decrease in the diameter of the left ventricle and recovery of systolic functions to normal ranges: the diastolic diameter of the left ventricle was 5.5 cm, systolic diameter, 3.9 cm, and ejection fraction was 55% (fig. 1b). In addition to the echocardiographic improvement, sinus bradycardia, ventricular extrasystoles and incomplete right bundle branch block on the initial ECG had returned to normal at the 6-month follow-up. Significant improvement in his functional capacity (from New York Heart Association class III back to class II) was observed. The patient stated that his complaints had largely disappeared, he had no shortness of breath in his daily physical activities and he could easily play basketball with his friends. Although the patient did no longer comply with treatment, no deterioration was observed with respect to the patient's complaints.

The patient was lost to follow-up during the following 2.5 years. We learned that he was serving his postponed compulsory military duty. A coronary angiographic examination due to an unknown indication performed at the military hospital during his military duty demonstrated neither structural nor functional lesions in his coronary arteries. The structure and function of the left ventricle continued to improve (fig. 2) in the absence of toluene abuse.



**Fig. 2.** Ventriculography of the case shows that left-ventricular systolic function was increased (ejection fraction: 72%) at the end of the 3-year period during which he did not sniff toluene vapor. Ventriculographic images during diastole (**a**) and systole (**b**) are shown; arrows indicate the width of the left ventricle during diastole and systole, respectively.

## Discussion

Paint thinners and adhesives sold in Turkey contain 50–70 and 35–40% toluene, respectively. Following inhalation or skin contact in the industrial setting, toluene rapidly diffuses into the blood and easily penetrates tissues that are rich in lipids such as the brain. In tissues, toluene is oxidized by monooxidase enzymes that are connected to cytochrome P<sub>450</sub>. As a result of this oxidation, free radicals are released. Therefore, increased amounts of malondialdehyde, a lipid peroxidation product, are found in the blood as well as glutathione peroxidase and superoxide dismutase, which are antioxidant enzymes found in the erythrocytes of workers employed in toluene-diisocyanate-manufacturing plants. Consequently, toluene inhalation increases lipid peroxidation and triggers the synthesis of antioxidant enzymes [18].

Experimental studies revealed that toluene inhalation causes morphological changes in the lung, liver, kidney, adrenal gland and in the central nervous system of mice in the short and long term (4 and 12 weeks, respectively) [19]. Nonspecific myocarditis findings were observed with the above-stated effects in a similar study performed in mice in Turkey.

In previously published studies, myocardial infarction has been associated with toluene inhalation. Recurrent ventricular fibrillation resistant to defibrillation and antiarrhythmic treatment was reported [13–15]. We hypothesized that toluene exerted direct cardiotoxic effects.

Toluene may render the heart susceptible to endogenous catecholamines or induce lipid peroxidation in addition to evident ischemia related to vasospasm, which may play an important role in the development of fatal rhythm problems. Moreover, coexisting electrolyte abnormalities caused by renal toxicity of this substance may also contribute to the development of fatal arrhythmias [20].

In our case, the diameter and systolic function of the left ventricle and mitral valve functioning completely returned to normal ranges after the patient had quit toluene inhalation. In addition, ventriculographic findings showing permanent improvement in the diameter and function of the left ventricle after 3 years were striking. In a similar case report from Poland, Lisowska et al. [21] noted atrial fibrillation and congestive heart failure in a toluene addict. Toxic cardiomyopathy was diagnosed in this patient, and his initial left-ventricular ejection fraction was 15%. In the absence of toluene use and following medical treatment, left ventricular ejection fraction increased to 45%.

ECG changes in the form of sinus bradycardia, bigeminal ventricular extrasystoles and incomplete right bundle branch block occurred concomitant with cardiomyopathy in our case. All these ECG changes were found to have improved at the 6-month follow-up. In another case sniffing adhesives, severe sinus bradycardia was also diagnosed. It was reported that the bradyarrhythmia similarly returned to normal in this case in the absence of the effect of the volatile substance. Zee-Cheng et al. [22] con-

cluded that some of the sudden deaths due to volatile substance inhalation might be related to bradyarrhythmia instead of ventricular tachyarrhythmias.

Taking into account that the function of the myocardium was completely or largely restored in the absence of substance use in cases with toluene-induced cardiomyopathy, it could be argued that the toxic effect of toluene on the heart muscle may be reversible. Similarly, myocardial dysfunction or segmental wall motion abnormalities was generally reversible in patients developing toluene-induced myocardial infarction. In summary, toluene had caused evident ischemia and myocardial infarction due to coronary vasospasm. Myocardial function had obviously returned to normal ranges in the absence of spasm. On the contrary, recurrent non-Q wave infarction associated with toluene inhalation may obviously result in permanent myocardial damage [15].

We assumed that the development of cardiomyopathy without evident ischemia symptoms might result from silent ischemic damage associated with toluene inhalation. The fact that toluene causes evident ischemia in some and silent ischemia in others may be related to both the dose and the duration of substance abuse and the possible genetic and environmental factors that increase the cardiotoxic effect of this substance. Furthermore, it should be mentioned that the direct cardiotoxic effect of toluene leading to the development of arrhythmia might affect the development of cardiomyopathy.

Consequently, in young patients, a possible cause of dilated cardiomyopathy may be toluene inhalation, and examination for cardiomyopathy is warranted in toluene addicts.

## References

- 1 Ögel K, Yücel H, Aksoy A: İstanbul'da sokakta yaşayan çocukların özellikleri. Yeniden Bilimsel Araştırma Raporları. Yayın no 7. İstanbul, 2004.
- 2 Ögel K, Taner S, Eke C, Erol B: İstanbul'da Onuncu Sınıf Öğrencileri Arasında Tütün, Alkol ve Madde Kullanım Yaygınlığı Raporu. Yeniden Yayın no 15. İstanbul, 2005.
- 3 Ögel K, Tamar D: Ruhsal Bozukluklar Epidemiyolojisi: Alkol ve madde kullanım bozuklukları epidemiyolojisi. Ege Psikiatri Sürekli Yayınları, 2000, p 124.
- 4 Davies B, Thorley A, O'Connor D: Progression of addiction carriers in young adult solvent misusers. *Br Med J (Clin Res Ed)* 1985;290:109–110.
- 5 Flanagan RJ, Ruprah M, Meredith TJ, Ramsey JD: An introduction to the clinical toxicology of volatile substances. *Drug Saf* 1990;5:359–383.
- 6 Escobar A, Aruffo C: Chronic thinner intoxication: clinico-pathologic report of a human case. *J Neurol Neurosurg Psychiatry* 1980;43:986–994.
- 7 Yamanouchi N, Okada S, Kodama K, et al: White matter changes caused by chronic solvent abuse. *Am J Neuroradiol* 1995;16:1643–1649.
- 8 Akisu M, Mir S, Genc B, Cura A: Severe acute thinner intoxication. *Turk J Pediatr* 1996;38:223–225.
- 9 Anderson HR, Dick B, Macnair RS, Palmar JC, Ramsay JD: An investigation of 140 deaths associated with volatile substance abuse in the United Kingdom (1971–1981). *Hum Toxicol* 1982;1:207–221.
- 10 Bass M: Sudden sniffing death. *JAMA* 1970;212:2075–2079.
- 11 Collison I, Moorehead W: Death by paint thinner. *J Anal Toxicol* 2002;26:532–536.
- 12 Gustavsson P, Plato N, Hallqvist J, et al: A population-based case-referent study of myocardial infarction and occupational exposure to motor exhaust, other combustion products, organic solvents, lead, and dynamite. Stockholm Heart Epidemiology Program (SHEEP) Study Group. *Epidemiology* 2001;12:222–228.
- 13 Cunningham SR, Dalzell GW, McGirr P, Khan MM: Myocardial infarction and primary ventricular fibrillation after glue sniffing. *Br Med J (Clin Res Ed)* 1987;294:739–740.
- 14 Carder JR, Fuerst RS: Myocardial infarction after toluene inhalation. *Pediatr Emerg Care* 1997;13:117–119.
- 15 Hussain TF, Heidenreich PA, Benowitz N: Recurrent non-Q-wave myocardial infarction associated with toluene abuse. *Am Heart J* 1996;131:615–616.
- 16 Wiseman MN, Banim S: 'Glue sniffer's' heart? *BMJ (Clin Res Ed)* 1987;294:739.
- 17 Knight AT, Pawsey CG, Aroney RS, Lawrence JR, Jones DB, Newland RC: Upholsterers' glue associated with myocarditis, hepatitis, acute renal failure and lymphoma. *Med J Aust* 1991;154:360–362.
- 18 Halifeoglu I, Canatan H, Ustundag B, Ilhan N, Inanc F: Effect of thinner inhalation on lipid peroxidation and some antioxidant enzymes of people working with paint thinner. *Cell Biochem Funct* 2000;18:263–267.
- 19 Carabez A, Sandoval F, Palma L: Ultrastructural changes of tissues produced by inhalation of thinner in rats. *Microsc Res Tech* 1998;40:56–62.
- 20 Kirk LM, Anderson RJ, Martin K: Sudden death from toluene abuse. *Ann Emerg Med* 1984;13:68–69.
- 21 Lisowska A, Skibinska E, Musial WJ: Severe heart failure due to toxic cardiomyopathy in a young patient – a case report. *Kardiol Pol* 2004;60:372–373.
- 22 Zee-Cheng CS, Mueller CE, Gibbs HR: Toluene sniffing and severe sinus bradycardia. *Ann Intern Med* 1985;103:482.